

Tips to Succeed the Desirable Trabeculectomy Blebs



Visanee Tantisevi, M.D.

Backgrounds

Trabeculectomy is still the wonderful glaucoma filtering surgery despite many of us believe it is not the perfect surgical intervention to intra-ocular pressure (IOP) lowering. Key concept is to create new exit (sclerostomy) and reservoir (subconjunctival space) for aqueous drainage because the conventional outflow passage has not worked sufficiently (either reduced its outflow capacity in open angle or inaccessible trabecular-meshwork in angle-closure glaucoma). Over the past few years, efforts of reconstructing the conventional aqueous outflow passage without exploitation of the conjunctiva or subconjunctival tissue (deep sclerectomy with or without viscocanalostomy) have been brought to challenge the trabeculectomy benefits.¹⁻⁷ However, in Asian eyes, it seems no solid evidence that those non-penetrating surgeries would work well. Trabeculectomy with anti-fibrosis agents, mitomycin c (MMC)

or 5-fluorouracil (5-FU), hence the procedure of choice for glaucoma filtering surgery accepted nation-wide and in most part of the world.

From the day it was first introduced by Cairns⁸, its IOP lowering effect has been challenged by the natural inflammatory reaction at the surgical site, particularly at the episclera and tenon level. That mentioned area, locates above the scleral flap and underneath conjunctiva, collects the aqueous from the anterior chamber and let the aqueous diffuse through the surrounding capillaries, keep the IOP down and in balance, is the bleb, named after its character. The inflammatory reaction leads to fibrosis and the final healing process downsizes the whole area, fail the bleb effect resulting in surgical failure.

To get the bleb survive and function longer, application of 5-fluorouracil (5-FU) or mitomycin-c (MMC) is currently accepted option.⁹⁻¹⁶ Concentration and duration to be used depend on many

factors, type of glaucoma, number of prior surgeries, limbal-based or fornix-based conjunctival flap or even surgeon's familiarity with the agents.

With the approved benefits, complications of over-draining or leaking bleb, cystic bleb with dysesthesia, even with the most serious bleb-related endophthalmitis do put anti-fibrotic agents usage at stake. To reduce undesirable effects and get good-looking final bleb appearance, many methods have been proposed. Not only individually adjusted concentration and duration of application are pre-determined, surgical technique of filtering surgery, trabeculectomy in particular, is in concerns and also modified.

Current concept of trabeculectomy

Peng T Khaw¹⁷ developed Moorfield Safe Surgery System (MSSS) and suggested the essence of how trabeculectomy should be, these are

1. Fornix-based conjunctiva incision rather than limbal-based in order to avoid bleb limitation due to posterior incision scar. Larger posterior pocket for drainage is also achieved through wider area of anti-fibrotic agent application.

2. Scleral flap should be large enough to cover the relatively small sclerostomy site because its main function is to prevent excessive aqueous flow that resulting in hypotony. Flap thickness more than 50% of the whole scleral thickness is advocated to reduce chance of cheese-wiring and button-hole suture tracts, securing its resistance. No matter what shape the flap is, side cut should not be completely directed towards limbus. This will allow aqueous drain more posteriorly and prevent future cystic bleb.

3. Intra-operative MMC or 5-FU should be applied in a wider fan-shaped into subconjunctival pocket which previously prepared. Such implementation helps achieving wider area and much more diffuse non-cystic bleb. Recommended MMC dosage and 5-FU are 0.2-0.5 mg/ml and 50 mg/ml

respectively. Irrigation the treated area with Balance Salt Solution after application of these agents is also important. Khaw has keyed his guideline of how to use MMC in whom. However, in Asian eyes, this tradition might be differently viewed and adjusted accordingly to each patient.

In his article, suturing technique of scleral flap and conjunctiva was also issued, providing the most secured bleb avoiding leakage. Suture material is also crucial because tissue cheese-wiring or button-hole is unwanted. Nonetheless, understanding its rationale is enough to develop our own technique. Suturing, therefore, is not as in regards as bleb reservoir area preparation.

Figure 1 shows the MSSS concept of trabeculectomy with permission from Peng T Khaw

To the author's viewpoint, this Moorfields system may be the most reliable. Considering the reason of glaucoma drainage device (GDD) development, factors that influence IOP control are total surface area and bleb capsule resistance. GDD plate maintained the draining surface area by limiting contracture after capsular formation.¹⁸⁻¹⁹ Trabeculectomy bleb can share the same concept by applying anti-fibrosis agent, implementing its property, to the desired area. The wider subconjunctival

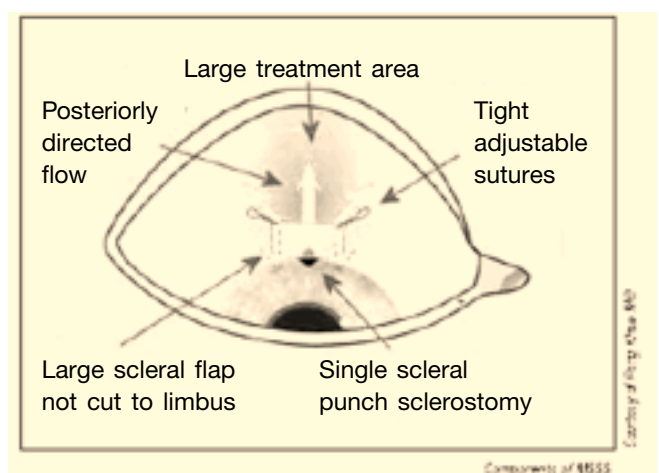


Figure 1 shows MSSS concept of trabeculectomy

pocket was treated, the much more surface area we could achieve.

Blebs we may get

Figure 2, 3 show limited area, avascular cystic bleb appearance surrounding by ring of steel (hyper-vascularized fibrosis around bleb area which limit its drainage) after filtering surgery with MMC.

What we learn from this occurrence perhaps are

1. Subconjunctival tissue was not undermined far and wide enough
2. MMC treated area was too limited
3. MMC concentration might be too much or

too longer MMC application

Figure 4, 5 show flat bleb appearance after 2 months post filtering.

Again, these photos give us a learning of

1. Too little area of subconjunctival pocket may have been prepared
2. Lesser MMC concentration or duration of application
3. Some post-operative intervention, for examples, laser suture lysis or subconjunctival 5-FU might be delayed

Therefore, it has led to bleb failure.

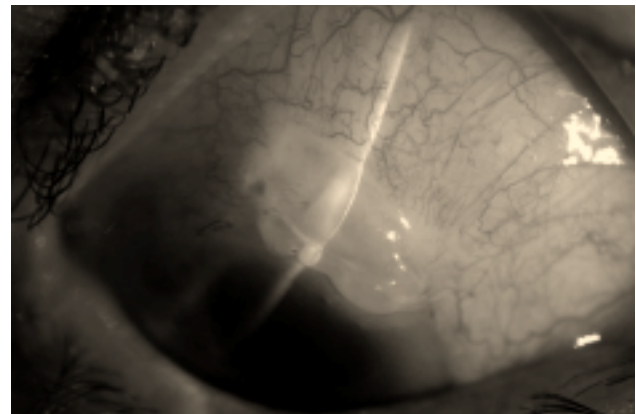
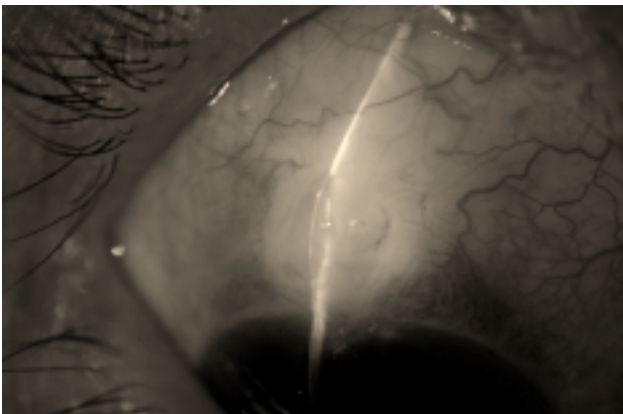


Figure 2, 3 shows anterior avascular, cystic blebs (รูปสีท้ายเล่ม)

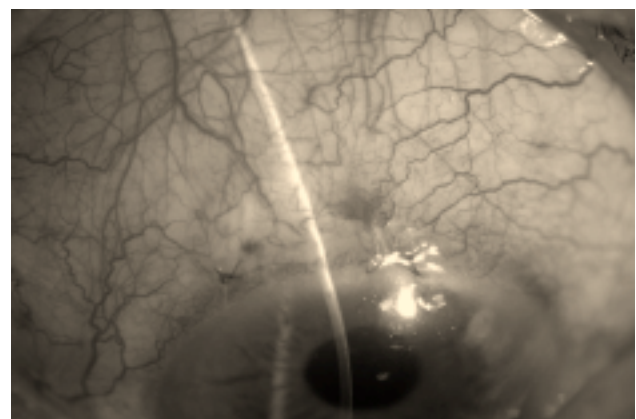
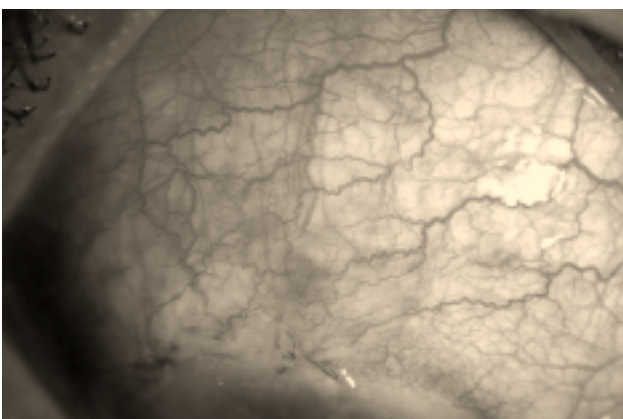


Figure 4, 5 shows flat bleb after 2 months post-surgery (รูปสีท้ายเล่ม)

Bleb we want

Figure 6 and 7 show more diffuse non-cystic bleb as desired in many forms

How come we get this awesome appearance?

Unsurprisingly, same philosophy as mentioned above.

1. Dissected sunconjunctival area as far as we could
2. Created scleral flap area large enough to cover the relative small sclerostomy site
3. Applied MMC-soaked sponges in a fan-shaped fashion more posteriorly

In the mean time, more lists to check

1. Properly strengthen scleral flap suture
2. Do not forget to test the aqueous flow

through scleral flap

3. Post-operative suture lysis at the right time or subconjunctival 5-FU/MMC if necessary

In summary

Trabeculectomy is basically easy surgery if we clearly understood its concept. However, to get the desirable successful outcome both anatomically and functionally need some practicing and learning. In every surgery has its own value and some beautiful tips hidden within. We can improve our surgical technique by combining our own experience with the others. Finally we will find what technique we suit most and showing us the best results we had wished for.

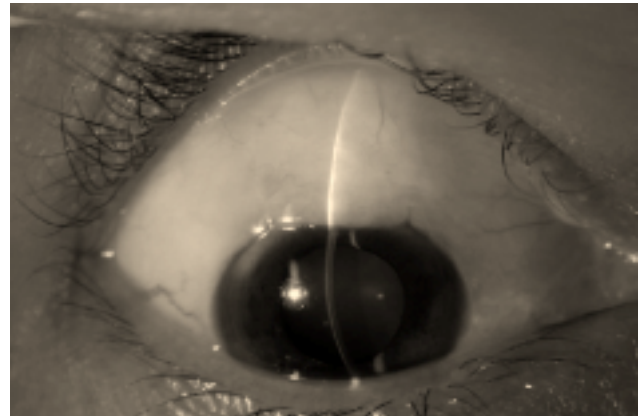
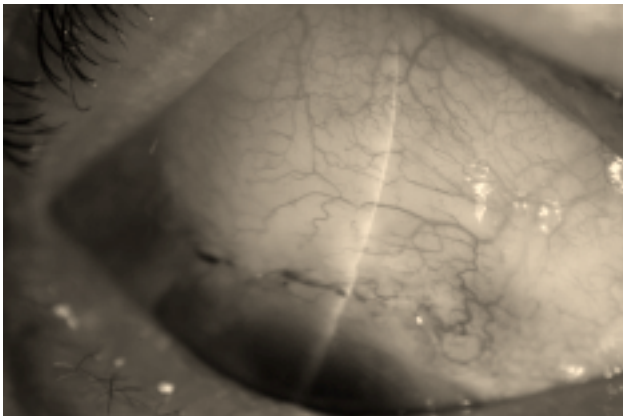


Figure 6 and 7 show more desirable diffuse, non-cystic blebs in many forms (รูปสี่ท้ายเล่ม)

References

1. Kreshner RM. Nonpenetrating trabeculectomy with placement of a collagen drainage device. J Cataract Refract Surg. 1995 Nov;21(6):608-11.
2. Welsh NH, DeLange J, Wasseman P, Ziemba SL. The "deroofting" of Schlemm's canal in patients with open-angle glaucoma through placement of a collagen drainage device. Ophthalmic Surg Lasers. 1998 Mar;29(3):216.
3. Mermoud A, Schnyder CC, Sickenberg M, Chiou AG, Hediguer SE, Faggioni R. Comparison of deep sclerectomy with collagen implant and trabeculectomy in open-angle glaucoma. J Cataract Refract Surg. 1999 Mar;25(3):323-31.
4. Mermoud A, Schnyder CC. Nonpenetrating filtering surgery in glaucoma. Curr Opin Ophthalmol. 2000 Apr;11(2):151-7. Review.
5. Netland PA; Ophthalmic Technology Assessment Committee Glaucoma Panel, American Academy of Ophthalmology. Non-

- penetrating glaucoma surgery. *Ophthalmology* 2001 Feb; 108 (2):416-21.
6. Goldsmith JA, Ahmed IK, Crandal As. Nonpenetrating glaucoma surgery. *Ophthalmol Clin North Am.* 2005 Sep;18(3): 443-60.
 7. Cillino S, Di Pace F, Casuccio A, Cillino G, Lodato G. Deep sclerectomy versus trabeculectomy with low-dosage mitomycin C: four-year follow-up. *Ophthalmologica* 2008;222(2):81-7. Epub 2008 Feb 22.
 8. Cairns JE. Trabeculectomy: preliminary report of a new method. *Am J Ophthalmol* 1968;66:673.
 9. Jacobi PC, Dietlein TS, Krieglstein GK. Adjunctive mitomycin C in primary trabeculectomy in young adults: a long-term study of case-matched young patients. *Graefes Arch Clin Exp Ophthalmol.* 1998 Sep;236(9):652-7.
 10. Rothman RF, Liebmann JM, Ritch R. Low-dose 5-fluorouracil trabeculectomy as initial surgery in uncomplicated glaucoma: long-term followup. *Ophthalmology.* 2000 Jun;107(6): 1184-90.
 11. Singh K, Mehta K, Shaikh NM, et al Trabeculectomy with intraoperative mitomycin C versus 5-fluorouracil: prospective randomized clinical trial. *Ophthalmology* 2000;107:2305.
 12. Bindlish R, Condon GP, Schlosser JD, D'Antonio J, Lauer KB, Lehrer R. Efficacy and safety of mitomycin-C in primary trabeculectomy: five-year follow-up. *Ophthalmology.* 2002 Jul;109(7):1336-41.
 13. Jongseereejit B, Tomidokoro A, Mimura T, Tomita G, Shirato S, Araie M. Efficacy and complications after trabeculectomy with mitomycin C in normal-tension glaucoma. *Jpn J Ophthalmol.* 2005 May-Jun;49(3):223-7.
 14. Shigeeda T, Tomidokoro A, Chen YN, Shirato S, Araie M. Long-term follow-up of initial trabeculectomy with mitomycin C for primary open-angle glaucoma in Japanese patients. *J Glaucoma.* 2006 Jun;15(3):195-9.
 15. Lazaro C, Garcia-Feijoo J, Castillo A, Perea J, Martinez-Casa JM, Garcia-Sanchez J. Impact of intraocular pressure after filtration surgery on visual field progression in primary open-angle glaucoma. *Eur J Ophthalmol.* 2007 May-Jun;17(3): 357-62.
 16. Law SK, Modjtahedi SP, Mansury A, Caprioli J. Intermediate-term comparison of trabeculectomy with intraoperative mitomycin-C between Asian American and Caucasian glaucoma patients: a case-controlled comparison. *Eye.* 2007 Jan;21(1):71-8. Epub 2005 Oct 14.
 17. Khaw PT, Shah P, Zeyen T. Trabeculectomy - The Moorfields Safe Surgery System (available from: URL:<http://www.ucl.ac.uk/iao/studentpdf/khaw%20safe%20surgery%20system.pdf>)
 18. Molteno AC. New implant for drainage in glaucoma. *Clinical trial. Br J Ophthalmol.* 1969 Sep;53(9):606-15.
 19. Molteno AC, Straughan JL, Ancker E. Long tube implants in the management of glaucoma. *S Afr Med J.*1976 Jun 26;50(27):1062-6.